

Biaction Technology, A Novel HA-Delivery System for Skin Remodelling: A Clinical Update

by
Sabine Zenker,
MD

Dermatologist, Munich,
Germany

Phone:

+49 89 552-769-0

Fax:

+49 89 552-769-11

Cell: +49 179 296-4367

Email:

kontakt@dr-zenker.de

www.dr-zenker.de

Disclosures: Dr Zenker
reports no relevant
financial interests.

ABSTRACT

Background

Airgent is an innovative standalone system for skin remodelling for indications otherwise difficult to treat. This article presents for the first time a clinical update on this new treatment option.

Objective

To explain the Airgent system mode of action, summarise its clinical results, published clinical trials, articles and case reports.

Discussion

The technology consists of a novel HA-delivery system that pneumatically introduces a jet of hyaluronic acid solution under high pressure into the dermis. A dermal trauma is created, and this targeted micro-trauma of the dermal structures consequently stimulates collagen-neogenesis on larger dermal surfaces in order to significantly thicken and remodel dermal structures. It is therefore, possible to treat difficult, delicate and challenging indications such as stretch marks, hypopigmented scars and acne scars, fine wrinkles and fine creases in large skin areas on the face, neck, hands, décolleté and other body areas.

My personal experience as one of the very early users is presented. I have conducted multiple pre-clinical and clinical investigations, clinical studies and multiple case reports demonstrating the short and long term efficacy and safety of this new skin remodelling device.

INTRODUCTION

Even though there are many existing treatment modalities for skin refining and skin remodelling in aesthetic medicine, there is still a lack of treatment options for difficult indications such as acne scars and hypotrophic scars, stretch marks, horizontal neck lines, fine wrinkles and fine creases. Current devices do not offer a treatment solution for large skin surfaces of the face, neck and décolleté where long downtime is not desired.

For these purposes, a new HA delivery modality for skin remodelling was developed, offering a new generation of non-invasive

approaches for treating skin surface conditions with minimum downtime. This technology enables for the first time the targeted and precise hyaluronic acid delivery by high pneumatic pressure into the dermis. The Airgent technology utilises a jet of HA to provoke a targeted and controlled deep intra dermal trauma to finally end up in a dermal thickening process with an augmentation of collagen in the dermis for safe, immediate and long-lasting aesthetic results.

It is well known that external addition of hyaluronic acid into the wound area induces a wound-healing mechanism that results in the formation of new healthy tissue instead of scar tissue¹. The technology utilises a combination effect: mechanical trauma caused by HA which penetrates to the dermal wound and takes part in the healing process.

OBJECTIVE

Fine skin lines, non-glowing skin on the face and décolleté, neck lines as well as scary tissue in acne scars, hypotrophic scars and stretch marks all have common characteristics: lack of healthy tensile strength of the dermal structures, loss of elasticity and tension^{2,3}, collagen decrease causes sagging, while loss of elastin results in lack of skin resilience. Ageing skin becomes thinner and more lax, contributing to the appearance of wrinkles⁴ and, in the case of scars, even the destruction of the normal dermal structures, which is replaced by scar tissue.

There are several energy-based skin rejuvenation technologies, such as lasers, radiofrequency, intense pulsed light (IPL), infrared light and photodynamic therapy which are aimed at triggering collagen remodelling in response to controlled thermal damage of the dermal skin layers⁵⁻²⁰. These techniques apply heat to provoke skin trauma. In general, efficacy is directly related to the amount of energy applied and so is downtime.

This report is intended to briefly present the Airgent clinical results so far and demonstrate its use as a safe and effective treatment modality.

MODE OF ACTION

The Airgent delivers diluted HA dermal filler solution into the dermis via pneumatic needleless action²⁷. The parameters of the high pressure injection and dose can be adjusted by the physician per indication, allowing focal introduction of the solution through the epidermis via a very minimal entry point²⁸.

Immediately following injection the skin is slightly elevated in the area of 0.8-1cm due to the lateral dispersion of the HA in a radial fashion along the dermis (Figure 1A), which is a result of the Airgent nozzle and jet profile.

The Airgent treatment side effects are minimal and include: slight bruising and bumps that disappear within a few hours, and entry points that can be easily concealed with makeup for the complete healing time which usually lasts 72 hours.

The high-impact delivery of HA dermal filler solution is proposed to effect two types of changes in the dermis. In the short-term, the volume of dermal filler and its water-attracting characteristic produce immediate volumisation. In the longer term, the described HA-induced effects stimulate fibroblasts¹, as well as induction of a wound healing response to form new healthy tissue in the treated area. Both are expected to produce longer lasting changes in the dermis (Figure 1A-1D, courtesy of PerfAction).

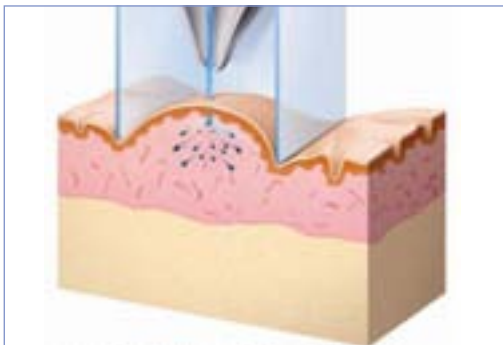


Figure 1A: An Airgent application. The square limiter is in contact with the skin, and the high-pressure jet is propelled from the handpiece without direct contact of the injector with the skin. ©PerfAction

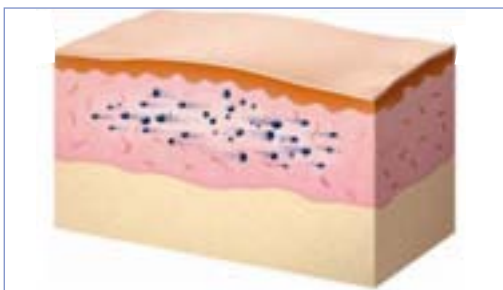


Figure 1B: Radial dispersion of the high molecular-mass solution introduced under high pressure. ©PerfAction

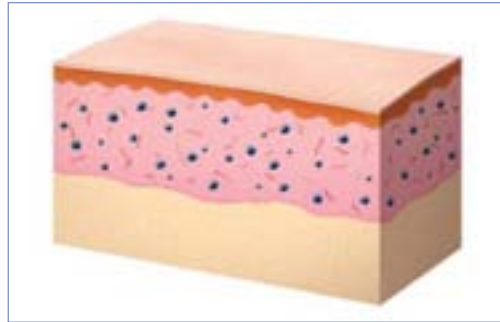


Fig. 1C: Several hours after treatment, the hyaluronic acid particles in the dermis attract water molecules, thickening and hydrating the dermis. ©PerfAction

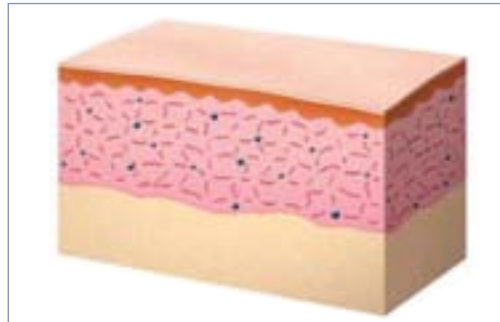


Fig. 1D: Proposed mechanism of action: long-term increase in collagen content is induced by natural wound healing and by the effects of hyaluronic acid on fibroblast stimulation. ©PerfAction

CLINICAL EVIDENCE

20MHz Ultrasound Imaging

The visualization of the intradermal placement of each HA-shot was performed by 20MHz ultrasound imaging: By Airgent Technology each HA bullet is correctly placed in the intradermal layer. And in addition -due to the Airgent unique technology - the HA spreads equally and laterally as well, to cover approximately and area of 1cm² (Figure 2):




Figure 2: This tissue regeneration capacity finally leads to a significant dermal thickening in both the short and the long term. This effect was shown by quantitative measurements following the Airgent™ treatment (24). (Figure 3)

Biaction
Technology,
A Novel HA-
Delivery
System for Skin
Remodelling:
A Clinical Update

by
Sabine Zenker,
MD

Dermatologist, Munich,
Germany

Phone:
+49 89 552-769-0

Fax:
+49 89 552-769-11

Cell: +49 179 296-4367

Email:
kontakt@dr-zenker.de
www.dr-zenker.de

Disclosures: Dr Zenker
reports no relevant
financial interests.

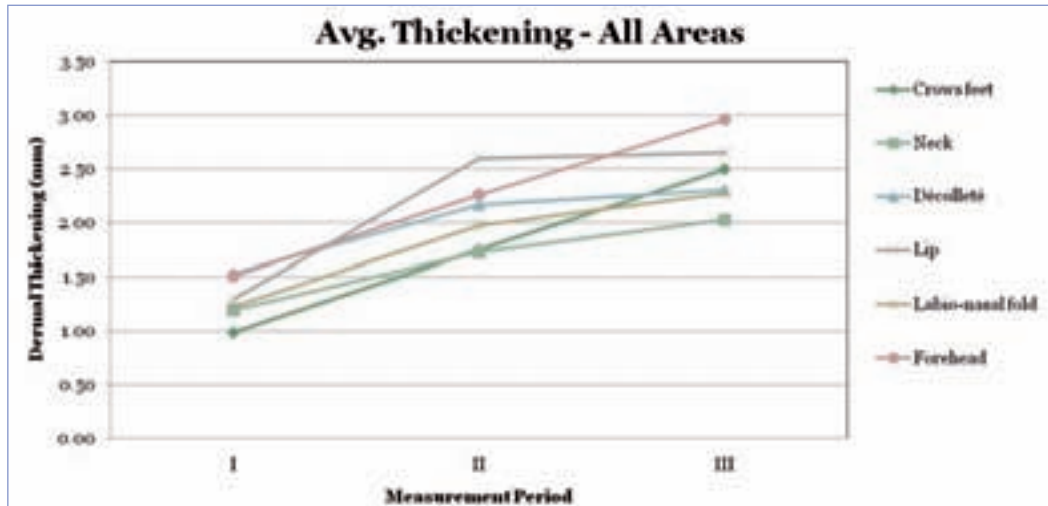
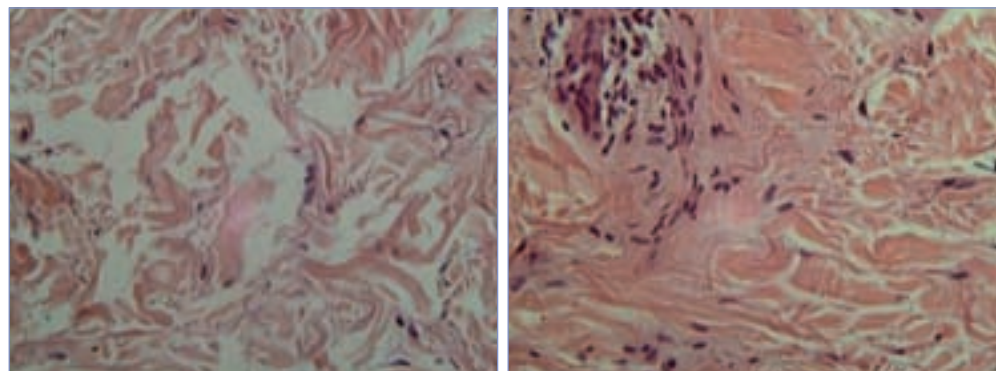


Figure 3: Dermal thickening in both deep, dynamic and superficial wrinkles.
Courtesy Kobus, K, Poland. Accepted for publication in Journal of Aesthetic Plastic Surgery.

Histology of Treated Skin

Histological analysis using H&E staining of a 39-year-old subject demis, 4 months following 3rd treatment in the aim.



Control site: dermis = 2.0mm

Treated site: dermis = 3.5mm

- Dermal thickening by x2
- An increase in number and density of collagen fibers
- No evidence of inflammatory infiltrate found at treated site or dermo-epidermal separation

Figure 4 (Courtesy of PerfAction)

HISTOLOGY

The regeneration capacity of dermal structures, notably the augmentation of collagen type III was shown by repeated skin biopsies. Reticulin staining highlights increased amount of collagen III fibers in the dermis of the treated area. (Figures 4,5):

RECENT STUDIES

To proof the efficacy and safety of this

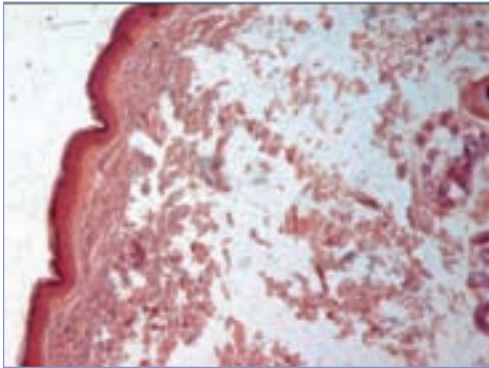
technology, several studies were driven:

"Quantitative measurements of dermal thickening short and long term following Airtgen treatment." Professor Kzimierz Kobus, plastic surgeon, Poland. Accepted for Publication in Journal of Aesthetic Plastic Surgery.

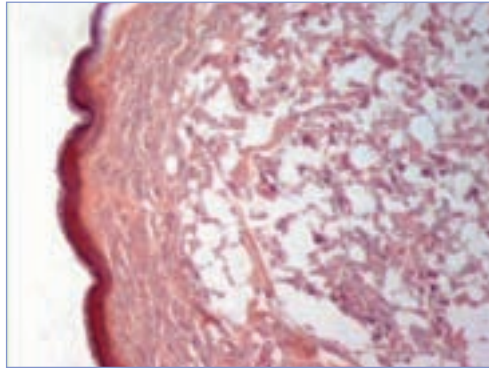
Summary of findings: 20 patients underwent 3 treatments in 3-4 week intervals in a total of 95 treatment sites. Each patient underwent measurement of the skin thickness by means

Histology of Treated Skin

Histological analysis using reticulin staining, of a 39-year-old subject demis, 4 months following 3rd treatment in the aim.



Control site: dermis = 1.6mm



Treated site: dermis = 3.0mm

- Dermal thickening by x2
- Increase amount of collagen-III reticular fibers

Figure 5 (Courtesy of PerfAction)

of ultrasonography: before the 1st treatment – Baseline; 1 week following three series of treatments; and months after the last treatment

Immediate results: 7 days after the last treatment skin thickening was observed in all patients. Six months after the series of treatments, increase in skin thickness was noticed in the majority of patients. The treatment with Airgent increased the thickness of the dermis, and led to significant improvement in appearance

“Clinical Results of Skin Remodeling Using Airgent, A Novel Pneumatic Technology.” Alex Levenberg, MD, Shlomit Halachmi, MD PhD, Abigail Arad-Cohen, MD, Dean Ad-El, MD, Daniel Cassuto, MD, Moshe Lapidoth, MD. Accepted for publication in the International Journal of Dermatology

Summary of findings: 52 patients underwent 1 to 3 treatments in 3-4 week intervals. Results: Photographic analysis demonstrated an excellent improvement in skin variables: significant visual improvement; protruding veins improvement in the palms; Fitzpatrick-Goldman Scale showed an entire wrinkle-class drop in both neck and face treatments. Forty-seven patients (out of 52) completed a self-assessment questionnaire: 77% of subjects expressed their satisfaction with the treatment. and its results. 83% stated they will recommend the treatment to friends and family.

“Treatment of Acne Scars Using Subdermal Minimal Surgery Technology” (equivalent to “Airgent Technology” comment by the

author), Airgent. Prof Beom Joom Kim, MD PhD, Jin Woong Lee, MD, Myeung Nam Kim, MD, Chang Kyun Lee MD, Department of Dermatology, Chung-Ang University College of Medicine, Chungdam Gwoonsesang Dermatologic Clinic 1, Seoul, Korea. Published in Dermatologic Surgery.

Summary of findings: 10 Korean patients with various acne scars received 3 treatments at 4-week intervals. Treatment parameters: 150ml 70% pressure per application. All volunteers completed the 3 treatment sessions and were satisfied with the procedure The majority of patients (6 of 10 patients) achieved a 50% to 75% improvement. Two patients had an improvement of greater than 75%, 2patients had a 25%-50% response to treatment There were no side effects except transient spot bleeding at entry points and a slight edema which resolved within 48 hours

Conclusion: Sub dermal minimal surgery technology (Airgent™) is an effective and safe method for improving acne scars

“Successful Treatment of Depressed Scars of the Forehead Secondary to Herpes Zoster Using Subdermal Minimal.” Beom Joon Kim, MD, Kwang Ho Yoo, MD, Myeung Nam Kim, MD. Published in Surgery Technology.

Summary of findings: The treatment was given once a month for 2 months. Anesthesia was administered before treatment by applying a topical anesthetic cream. The treatment parameters were one shot at 200ml at 80% pressure power. The patient did not report any

**Biaction
Technology,
A Novel HA-
Delivery
System for Skin
Remodelling:
A Clinical Update**

by
**Sabine Zenker,
MD**

Dermatologist, Munich,
Germany

Phone:
+49 89 552-769-0
Fax:
+49 89 552-769-11
Cell: +49 179 296-4367
Email:
kontakt@dr-zenker.de
www.dr-zenker.de

Disclosures: Dr Zenker
reports no relevant
financial interests.

pain or during the treatment. No side effects were evident except some spot bleeding at the injection sites and slight edema that resolved within Conclusion: 48 hours. Initial noticeable improvement was noted after 2 months of treatment, with slight elevation, and the lesion showed marked improvement after 6 months. The patient was satisfied with the treatment outcome. This study may support the clinical efficacy of The Airgent in revising the scars produced by herpes zoster. This technique might be applied in various fields of dermatologic scars and surgical scars with excellent clearance in an easy and safe

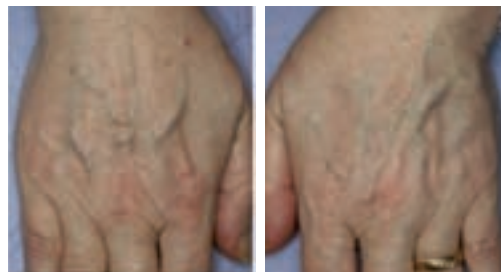CLINICAL EXAMPLES

Hands

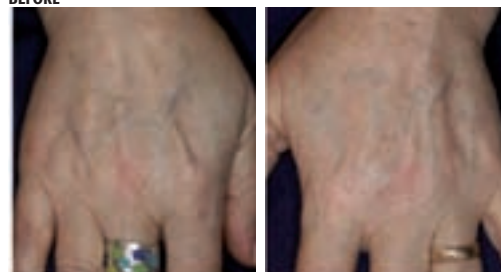Depressed Scar Following Herpes Zoster Forehead

Stretch Marks – to show the effect of Airgent Technology on stretch marks, multiple case reports can be summarized:

Stretch marks are among the most difficult skin conditions to treat. Either they do not respond to the existing treatment or the side effects of e.g. skin resurfacing options aren't acceptable. To evaluate the efficacy of immediate and long term improvement in treating red and white stretch marks, of this new treatment approach, studies are currently

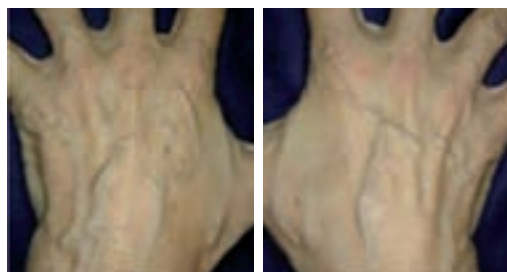

BEFORE

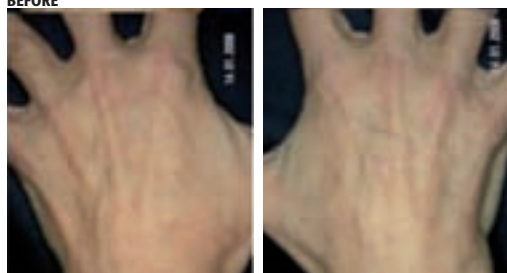

AFTER

Figure 7: Dorsal hands. 50-year-old female; before and 5 months after the 4th treatment. Photos Courtesy PerfAction

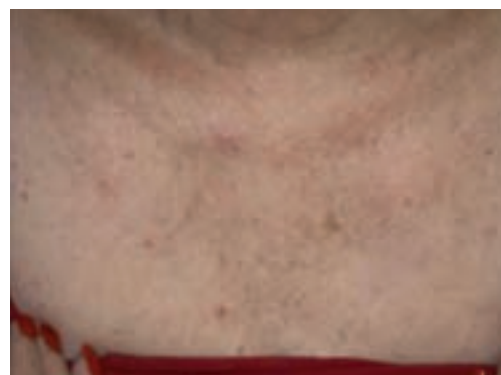

BEFORE

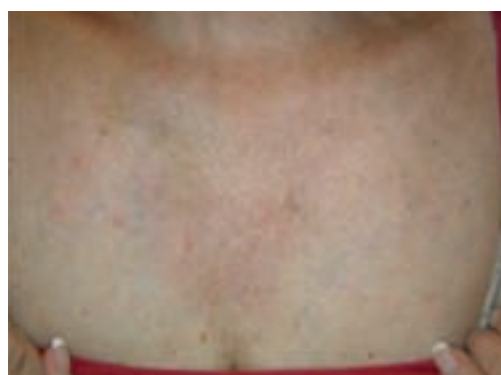

AFTER

Figure 6: Dorsal hands. 55-year-old female; before and 1 month after the 2nd treatment. Photos Courtesy PerfAction



BEFORE



AFTER

Figure 8: Chest. 55-year-old female; before and 1 month after 2nd treatment. Photos Courtesy PerfAction

conducted in various centers worldwide. The first results are very promising:

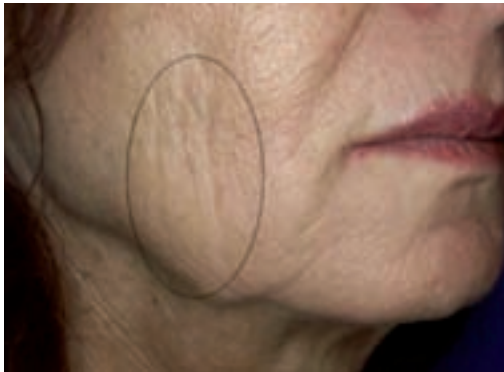Horizontal Neck Lines – Multiple case reports show good results on special indications such as horizontal neck lines.

CONCLUSION

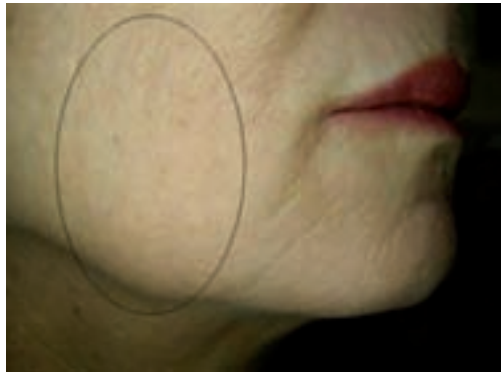Airgent Technology provides a safe and effective method of skin remodeling for the treatment of indications otherwise difficult to

deal with. All reported cases so far showed a long lasting improvement of the appearance of wrinkles or vein prominence as well as of those from stretch marks and acne scars in treatment of the aging face, neck, décolleté and hands.

No treatment technique previously available offered low-downtime improvement in skin appearance on large skin areas with immediate, short-term, and long-term results.

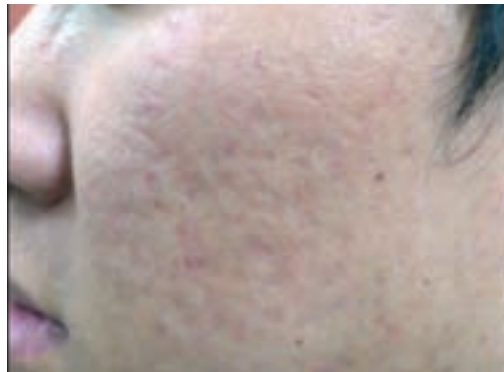

BEFORE

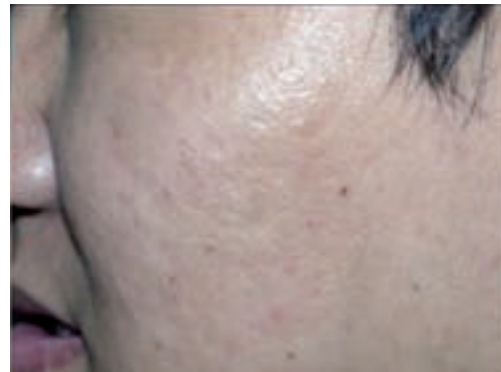

AFTER

Figure 9: Central region of the cheek. 58 year old female; 1 month after 2nd treatment. Photos Courtesy PerfAction

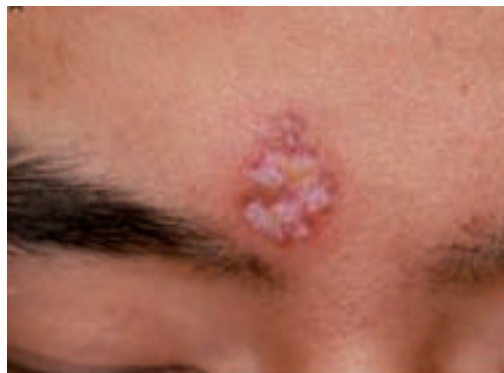

BEFORE

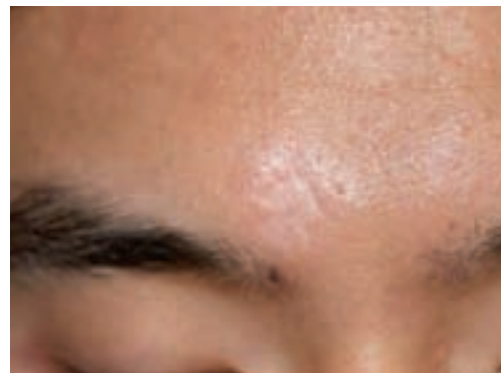

AFTER

Figure 10: Acne scars lateral cheeks. Male; 1 month after 2nd treatment. Photos Courtesy Dr Lee



BEFORE



AFTER

Figure 11: Depressed Scar Forehead; 6 months after 6th treatment. Photos Courtesy Prof Kim, Korea

Biaction
Technology,
A Novel HA-
Delivery
System for Skin
Remodelling:
A Clinical Update

by
Sabine Zenker,
MD

Dermatologist, Munich,
Germany

Phone:
+49 89 552-769-0
Fax:
+49 89 552-769-11
Cell: +49 179 296-4367
Email:
kontakt@dr-zenker.de
www.dr-zenker.de

Disclosures: Dr Zenker
reports no relevant
financial interests.

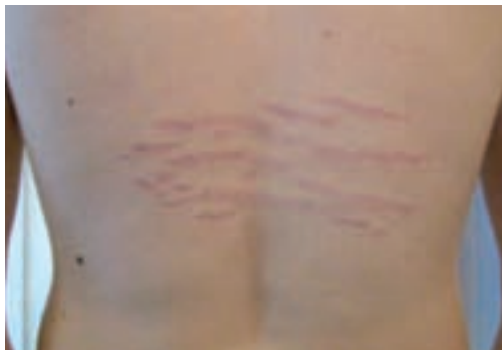

BEFORE

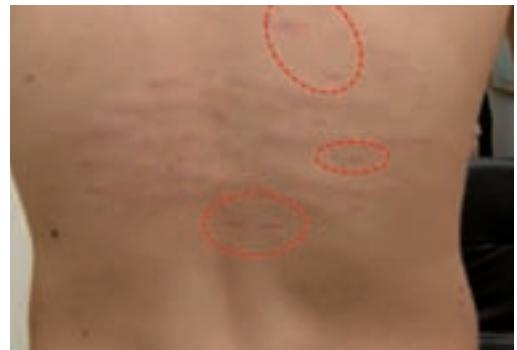

AFTER

Figure 12: Back. 17-year-old male; 1 month after 1st treatment. Photos Courtesy PerfAction

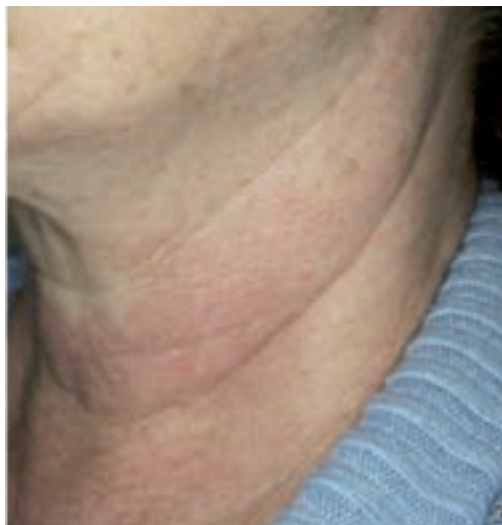

BEFORE

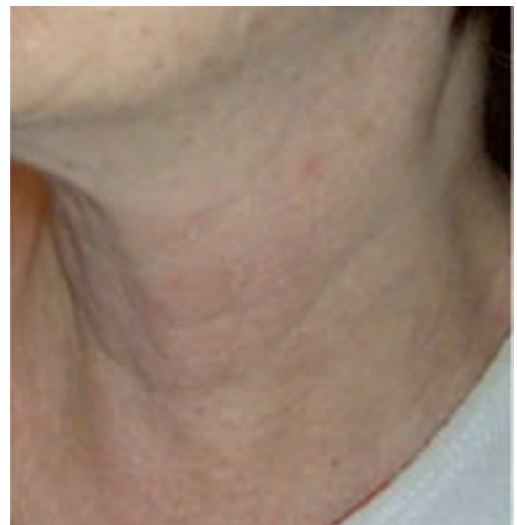

AFTER

Figure 13: Back. Same patient (Figure 17) one year later. Photos Courtesy PerfAction. Nite: New stretch marks, circled red, were not treated.

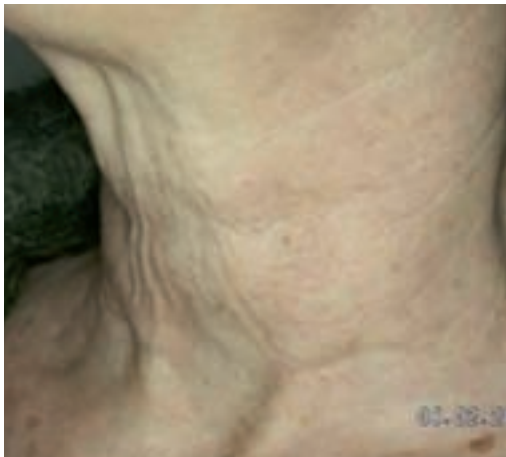

BEFORE

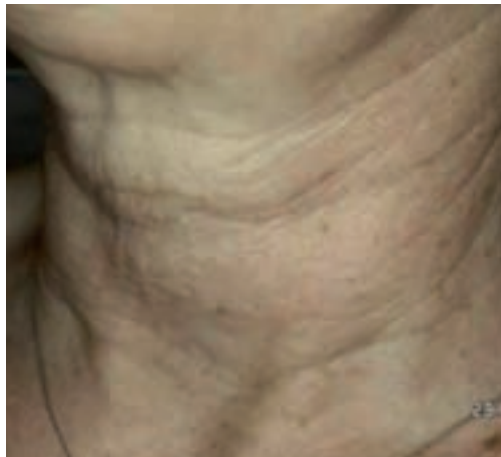

AFTER

Fig. 14 Horizontal neck lines. 52 year old female; before and 18 months after the 3rd treatment. Photos Courtesy PerfAction

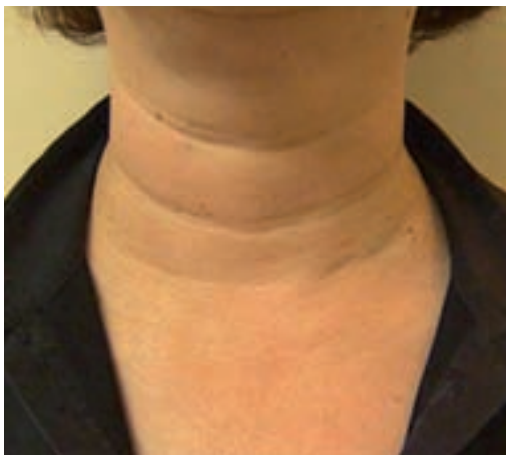


BEFORE

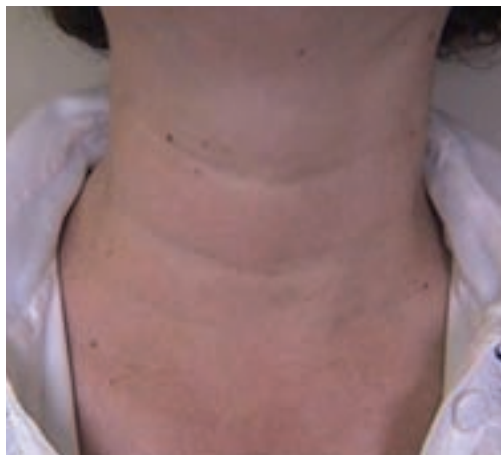

AFTER

Fig. 15 Neck. 51 year old female; 1 month after 2nd treatment. Photos Courtesy PerAction



BEFORE



AFTER

Fig. 16 Horizontal Neck Lines. 50 year old Female; 3 months after 3rd treatment. Photos Courtesy Dr Sabine Zenker

REFERENCES

1. Lynn L.H. Huang-Lee, Julia H. Wu, and Marcel E. Nimmi: Effects of hyaluronan on collagen fibrillar matrix contraction by fibroblasts. *Journal of Biomedical Materials Research*, Vol. 28, 123-132 (1994).
2. Fisher, GJ, Varani J, and Voorhees JJ, Looking older: Fibroblast collapse and therapeutic implications. *Arch Dermatol*, 2008. 144(5): p. 666-72.
3. Uitto, J and Bernstein EF, Molecular mechanisms of cutaneous aging: Connective tissue alterations in the dermis. *J Invest Dermatol Symp Proc*, 1998. 3(1): p. 41-4.
4. Ramos-e-Silva, M and da Silva Carneiro SC, Elderly skin and its rejuvenation: Products and procedures for the aging skin. *J Cosmet Dermatol*, 2007. 6(1): p. 40-50.
5. Nelson, JS, Majaron B, and Kelly KM, What is nonablative photorejuvenation of human skin? *Semin Cutan Med Surg*, 2002. 21(4): p. 238-50.
6. Hruza, GJ, Rejuvenating the aging face. *Arch Dermatol*, 2004. 140(11): p. 1383-6.
7. Herne, KB and Zachary CB, New facial rejuvenation techniques. *Semin Cutan Med Surg*, 2000. 19(4): p. 221-31.
8. Dover, JS and Zelickson B, Results of a survey of 5,700 patient monopolar radiofrequency facial skin tightening treatments: Assessment of a low-energy multiple-pass technique leading to a clinical end point algorithm. *Dermatol Surg*, 2007. 33(8): p. 900-7.
9. Weiss, RA, Gold M, Bene N, Biron JA, Munavalli G, Weiss M, and Beasley K, Prospective clinical evaluation of 1440-nm laser delivered by microarray for treatment of photoaging and scars. *J Drugs Dermatol*, 2006. 5(8): p. 740-4.
10. Alexiades-Armenakas, M, Dover JS, and Arndt KA, Unipolar versus bipolar radiofrequency treatment of rhytides and laxity using a mobile painless delivery method. *Lasers Surg Med*, 2008. 40(7): p. 446-53.
11. Grekin, RC, Tope WD, Yarborough JM, Jr., Olhoffer IH, Lee PK, Leffell DJ, and Zachary CB, Electrosurgical facial resurfacing: A prospective multicenter study of efficacy and safety. *Arch Dermatol*, 2000. 136(11): p. 1309-16.
12. Sadick, NS, Combination radiofrequency and light energies: Electro-optical synergy technology in esthetic medicine. *Dermatol Surg*, 2005. 31(9 Pt 2): p. 1211-7; discussion 1217.
13. Yu, CS, Yeung CK, Shek SY, Tse RK, Kono T, and Chan

**Biaction
Technology,
A Novel HA-
Delivery
System for Skin
Remodelling:
A Clinical Update**

**by
Sabine Zenker,
MD**

Dermatologist, Munich,
Germany

Phone:
+49 89 552-769-0
Fax:
+49 89 552-769-11
Cell: +49 179 296-4367
Email:
kontakt@dr-zenker.de
www.dr-zenker.de

Disclosures: Dr Zenker
reports no relevant
financial interests.

- HH, *Combined infrared light and bipolar radiofrequency for skin tightening in asians. Lasers Surg Med*, 2007. 39(6): p. 471-5.
14. Gold, MH, Goldman MP, Rao J, Carcamo AS, and Ehrlich M, *Treatment of wrinkles and elastosis using vacuum-assisted bipolar radiofrequency heating of the dermis. Dermatol Surg*, 2007. 33(3): p. 300-9.
15. Nestor, MS, Gold MH, Kauvar AN, Taub AF, Geronemus RG, Ritvo EC, Goldman MP, Gilbert DJ, Richey DF, Alster TS, Anderson RR, Bank DE, Carruthers A, Carruthers J, Goldberg DJ, Hanke CW, Lowe NJ, Pariser DM, Rigel DS, Robins P, Spencer JM, and Zelickson BD, *The use of photodynamic therapy in dermatology: Results of a consensus conference. J Drugs Dermatol*, 2006. 5(2): p. 140-54.
16. Gold, MH, *Photodynamic therapy update 2007. J Drugs Dermatol*, 2007. 6(11): p. 1131-7.
17. Goldberg, DJ, *Photodynamic therapy in skin rejuvenation. Clin Dermatol*, 2008. 26(6): p. 608-13.
18. Dover, JS, Bhatia AC, Stewart B, and Arndt KA, *Topical 5-aminolevulinic acid combined with intense pulsed light in the treatment of photoaging. Arch Dermatol*, 2005. 141(10): p. 1247-52.
19. Weiss, RA, Weiss MA, Munavalli G, and Beasley KL, *Monopolar radiofrequency facial tightening: A retrospective analysis of efficacy and safety in over 600 treatments. J Drugs Dermatol*, 2006. 5(8): p. 707-12.
20. Nouri, K, Rivas MP, Bouzari N, and Faghil S, *Nonablative lasers. J Cosmet Dermatol*, 2006. 5(2): p. 107-14.
21. Kono, T, Kinney BM, Groff WF, Chan HH, Ercocen AR, and Nozaki M, *Randomized, evaluator-blind, split-face comparison study of single cross-linked versus double cross-linked hyaluronic acid in the treatment of glabellar lines. Dermatol Surg*, 2008. 34 Suppl 1: p. S25-30.
22. Gold, MH, *What's new with hyaluronic acid fillers. J Drugs Dermatol*, 2007. 6(10): p. 1050-3.
23. Gold, MH, *Use of hyaluronic acid fillers for the treatment of the aging face. Clin Interv Aging*, 2007. 2(3): p. 369-76.
24. Kelly, PE, *Injectable success: From fillers to botox. Facial Plast Surg*, 2007. 23(1): p. 7-18; discussion 19-20.
25. Lupo, MP, *Hyaluronic acid fillers in facial rejuvenation. Semin Cutan Med Surg*, 2006. 25(3): p. 122-6.
26. Wang, F, Garza LA, Kang S, Varani J, Orringer JS, Fisher GJ, and Voorhees JJ, *In vivo stimulation of de novo collagen production caused by cross-linked hyaluronic acid dermal filler injections in photodamaged human skin. Arch Dermatol*, 2007. 143(2): p. 155-63.
27. Mitragotri, S, *Current status and future prospects of needle-free liquid jet injectors. Nat Rev Drug Discov*, 2006. 5(7): p. 543-8.
28. Levenberg A et al, *Clinical Results of Skin Remodeling Using Airgent, A Novel Pneumatic Technology*, 2009. Accepted for publication in the *International Journal of Dermatology*.
29. Martin, P, *Wound healing--aiming for perfect skin regeneration. Science*, 1997. 276(5309): p. 75-81.
- Dr Sabine Zenker is a dermatologist at the Dermatology Surgery Clinic, Maximilianstr 36, D-80539 Munich. T: +49-89-55 27 69-0; F: +49-89-55 27 69-11; E: kontakt@dr-zenker.de; W: www.dr-zenker.de