

4. Miteva M, de Farias DC, Zaiac M, Romanelli P, Tosti A. Nail clipping diagnosis of onychomatricoma. *Arch Dermatol* 2011;147:1117–8.
5. Perrin C, Langbien L, Schweizer J, Cannata G, et al. Onychomatricoma in the light of the microanatomy of the normal nail unit. *Am J Dermatopath* 2011;33:131–9.

MICHAEL S. GRAVES, MD
 J. KELLY ANDERSON, BS
*Section of Dermatology
 Medical College of Georgia
 Georgia Regents University
 Augusta, Georgia*

KEITH G. LEBLANC JR, MD
*The Skin Surgery Centre
 Metairie, Louisiana*

DANIEL J. SHEEHAN, MD
*Section of Dermatology
 Medical College of Georgia
 Georgia Regents University
 Augusta, Georgia*

The authors have indicated no significant interest with commercial supporters.

A Novel Facial Rejuvenation Treatment Using Pneumatic Injection of Non-Cross-Linked Hyaluronic Acid and Hypertonic Glucose Solution

Expectations for minimally invasive procedures have increased recently in the field of cosmetic surgery because of the large number of patients hoping to avoid invasive surgery. “Subdermal minimal surgery” technology, a computerized system that enables the targeted delivery of a jet of a solution by high pneumatic pressure through a tiny orifice, is a novel therapeutic modality for dermal remodeling procedures, such as those involving neck wrinkles, keloids, and depressed scars due to acne or herpes zoster.^{1–4} In previous clinical studies, it was suggested that pneumatically injected hyaluronic acid (HA) particles promote wound healing and induce neocollagenesis.^{1–4} The authors have applied this pneumatic technology to nonsurgical facial tightening, modifying the technology to suit the specific needs of this procedure.

Treatment Procedures

The injection system (Enerjet; PerfAction Ltd., Rehovot, Israel) consisted of a central console, applicator, and sterile disposable kit mounted on an applicator. The applicator was filled with a mixed solution of 1 mL non-cross-linked HA (Artz; Seikagaku Corporation, Tokyo, Japan) and 9 mL 20% glucose

solution (Fuso Pharmaceutical Industries, Osaka, Japan), which were compounded using a sterile 3-way stopcock and 2 syringes. The authors expected that the

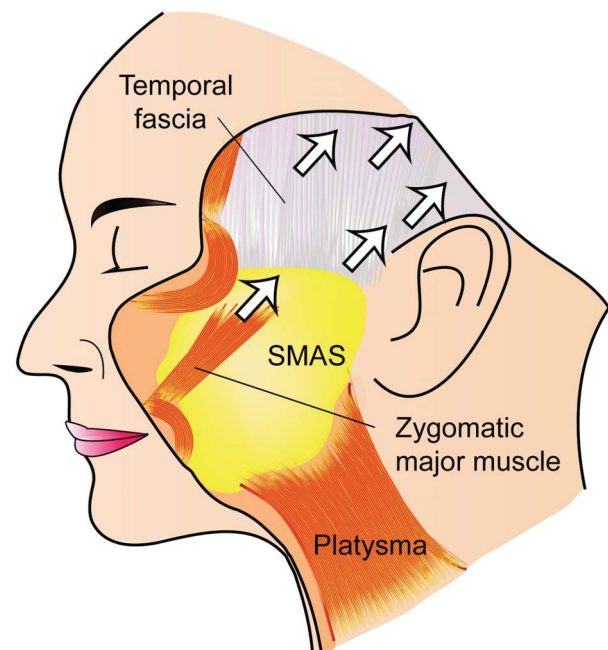


Figure 1. Placement of the pneumatic injections (white arrows). Temporal along the hairline, temporal within the main hair mass, supra-auricular, preauricular along the zygomatic arch, and malar prominence. SMAS, superficial musculoaponeurotic system.

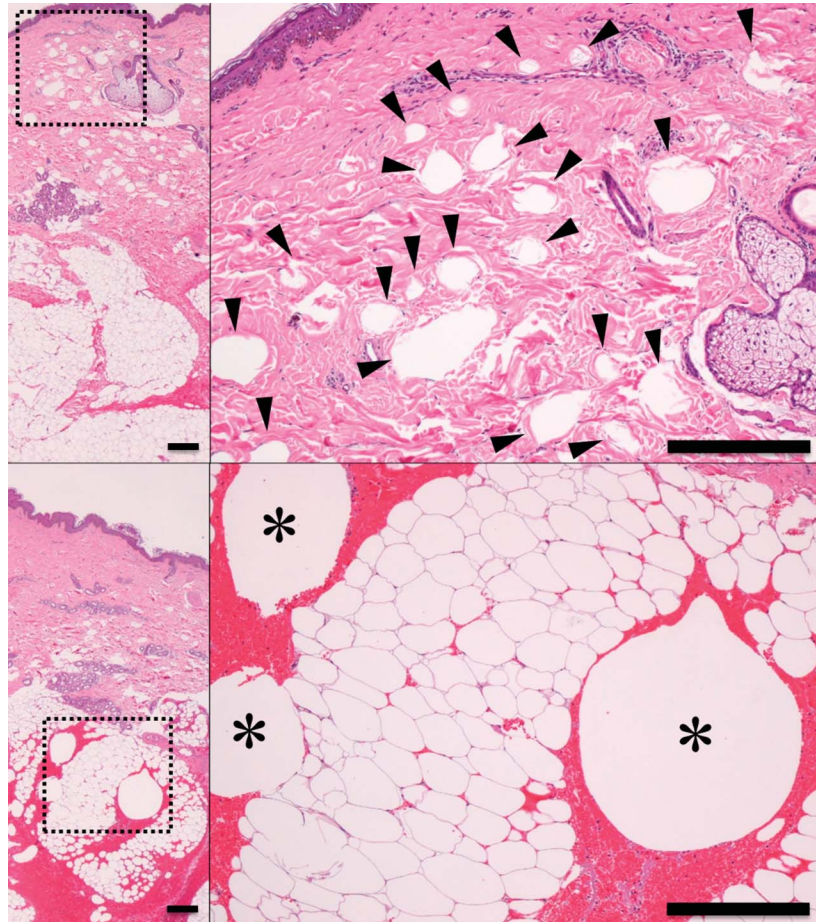


Figure 2. Histological analysis of the depth of the pneumatic injection. A 35-year-old man received a pneumatic injection of the mixed solution (1 mL HA and 9 mL 20% glucose solution) on his forearm, and the specimen taken immediately after the injection were stained with hematoxylin and eosin. (Upper) With 50% pressure power and 0.15 mL volume per shot, the solution (black arrow heads) was laterally dispersed in the whole dermis (scale bars = 500 μ m). (Lower) With 85% pressure power and 0.08 mL volume per shot, the solution (*) reached to the subcutis forming larger and fewer droplets, indicating deeper penetration of the solution (scale bars = 500 μ m).

high tonicity of the glucose solution enhances the inflammatory response, and hence, wound healing cascade. With the injection system, the operator can select these treatment parameters: injection volume and pressure power.

The pneumatic injections were applied at 5 target sites: 4 along the temporal hairline (preauricular along the zygomatic arch, supra-auricular, temporal along the hairline, and temporal within the main hair mass) and 1 at the malar prominence, with the aim of tightening and contracting the subcutaneous layer such as superficial musculoaponeurotic system (Figure 1). The treatment parameters were set to a “1-shot volume” of 0.08 mL and “pressure power”

of 85%, smaller 1-shot volume and higher pressure than those used in previous studies.¹⁻⁴ These parameters were specifically chosen to promote penetration into the deeper layers, based on findings from the preliminary experimental study (Figure 2). Thirty consecutive Japanese patients, aged from 41 to 69 years, underwent 3 sessions of treatment at 4-week intervals. The patients with a history of facial rejuvenation treatments in the previous 3 years were excluded.

Clinical outcomes were objectively assessed by comparing photographs taken before, 1 month, and 6 months after the final treatment. As a result, more than half of the patients showed mild to

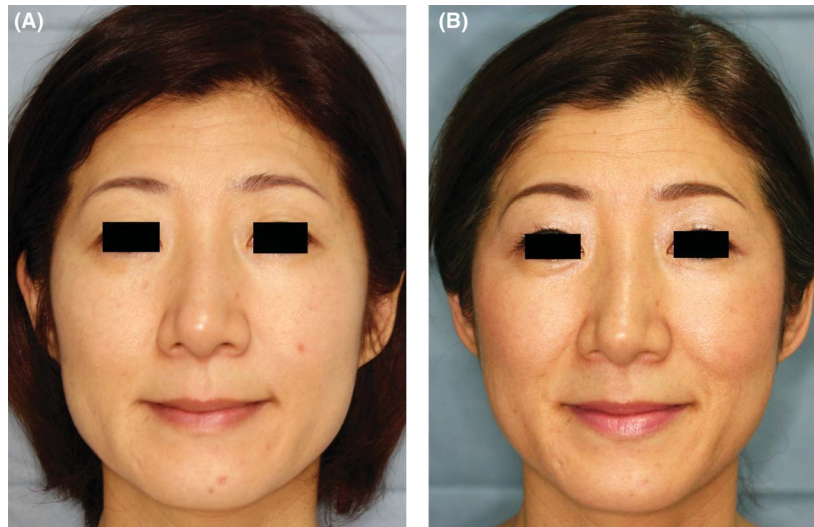


Figure 3. Photographic images of a representative case. This 45-year-old woman underwent 3 sessions of treatment. (A) Preoperative view. (B) View at 1 month after the last treatment.

moderate improvement in aging face, especially in the lower face: jawline and marionette lines (Figure 3). However, aesthetic improvement obtained in this treatment was substantially less than that seen with surgical face-lifts, and partial loss of correction over time was observed in comparison of 1- and 6- month follow-up. It is presumably because the effects due to tissue alteration such as the collagen remodeling persisted for a few months and gradually disappeared over the following months.

Also, patients' self-assessment of the overall appearance of the entire face was conducted at 6-month follow-up after the final treatment. Most of the patients were satisfied with the treatment, suggesting the stretched feeling of the facial skin, which was difficult to detect with photographic assessment. They also reported that the stretched feeling occurred 1 to 2 weeks after each treatment, indicating completion of the inflammatory phase and beginning of the proliferative phase in which wound contraction occurs. The mean pain score using visual analog scale (VAS) was 2.0. No serious complications (e.g., intense postoperative pain, local irritation, persistent erythema, apparent bruising, nerve injury, skin necrosis, or foreign body reaction) occurred, except postinflammatory hyperpigmentation (PIH) in the malar prominence in 2 patients.

Discussion

The authors performed 2 modifications of the pneumatic technology procedures used in previous studies of dermal remodeling treatment: (1) refining the treatment parameters to enable deeper penetration and (2) using hypertonic 20% glucose solution to enhance the inflammatory response. Similar mechanism of high tonicity has been proposed for prolotherapy,⁵ and hypertonic stimulation in the treatment remained within the bounds of safety as indicated by the mild VAS pain scores and the absence of serious complications.

A variety of therapeutic modalities for facial rejuvenation are available now, and such techniques as lasers, intense pulsed light, radiofrequency, and ultrasound use the concept of thermal tissue injury to accelerate the wound healing process. However, deep penetration of thermal damage is inevitably accompanied by adverse skin effects such as burns and long-lasting PIH, especially in Asian patients. Thus, the effectiveness of pneumatic injection through tiny openings holds the possibility of surpassing these heat-induced techniques by directly applying stimuli to the subcutaneous tissues, although further modifications are needed.

The results of 30 cases suggested the potential of pneumatic injection of non-cross-linked HA and

hypertonic glucose solution as a novel facial rejuvenation treatment with minimal morbidity and little patient discomfort. The main limitation of this study is the lack of a control group, and the authors cannot conclude whether the aesthetic outcomes originated from the HA, 20% glucose solution, the pneumatic pressure system, or all. However, this is a pilot study that sought to investigate the application of pneumatic pressure system to facial rejuvenation, and further studies are required to optimize the treatment protocol including the placement of injections and the solution component.

Acknowledgments The authors thank Dr. Munehiro Yokoyama for pathological analysis.

References

- Han TY, Lee JW, Lee JH, Son SJ, et al. Subdermal minimal surgery with hyaluronic acid as an effective treatment for neck wrinkles. *Dermatol Surg* 2011;37:1291–6.
- Kim HK, Park MK, Kim BJ, Kim MN, et al. The treatment of keloids with pneumatic technology: a pilot study. *Int J Dermatol* 2012;51:1502–7.
- Lee JW, Kim BJ, Kim MN, Lee CK. Treatment of acne scars using subdermal minimal surgery technology. *Dermatol Surg* 2010;36:1281–7.
- Kim BJ, Yoo KH, Kim MN. Successful treatment of depressed scars of the forehead secondary to herpes zoster using subdermal minimal surgery technology. *Dermatol Surg* 2009;35:1439–40.
- Rabago D, Best TM, Zgierska AE, Zeisig E, et al. A systematic review of four injections therapies for lateral epicondylitis: prolotherapy, polidocanol, whole blood, and platelet-rich plasma. *Br J Sports Med* 2009;43:471–81.

TAKANOBU MASHIKO, MD
*Department of Plastic Surgery
 School of Medicine, University of Tokyo
 Tokyo, Japan*

YOSHIHISA ABO, MD
*Department of Surgery
 North Aoyama D Clinic
 Tokyo, Japan*

SHINICHIRO KUNO, MD
 KOTARO YOSHIMURA, MD
*Department of Plastic Surgery
 School of Medicine, University of Tokyo
 Tokyo, Japan*

The authors have indicated no significant interest with commercial supporters.

Laser Skin Resurfacing During Isotretinoin Therapy

It is believed that laser procedures should not be performed until 6 to 12 months after the completion of isotretinoin/Accutane therapy. Published studies suggest that laser hair removal with a diode laser, an intense pulsed light, and a neodymium-doped yttrium aluminum garnet (Nd:YAG) laser is safe in patients during treatment with isotretinoin.^{1–4} Yoon and colleagues published their data, where they treated 35 patients with acne scars using a 1,550-nm fractional laser. All subjects were started on isotretinoin 10 mg/d for more than 1 month before the laser treatment. None of these patients developed scars.⁵ The experiment described here is an attempt to start exploring the possibility of treating acne scars with lasers while patients are on isotretinoin.

Materials and Methods

In a 19-year-old man in his fourth month of treatment at a 40 mg twice a day dose of isotretinoin, 3 sites

were marked on the lower back. One site was treated with a nonablative fractional laser, one with ablative fractional laser, and the third with full ablative laser. The nonablative fractional site was treated with 100 mJ/mB, 10-mm spot, 15 milliseconds, 3 passes using a diode 1,540-nm laser. The ablative fractional site was treated with 91 J/cm², rep rate of 30 Hz, 3 passes using an erbium:YAG 2,940-nm laser. The full ablative site was treated at 2 J, 5-mm spot, 8 Hz, 8 passes using an erbium:YAG 2,940-nm laser. A 4-mm punch biopsy was performed at each treatment site at each follow-up visit.

Results

At 6-month follow-up visit, nonablative fractional and ablative fractional treated sites showed normal appearing skin with mildly erythematous scars at the biopsy sites, whereas full ablative laser treatment site